

See discussions, stats, and author profiles for this publication at: <https://www.researchgate.net/publication/356965871>

# Safety, efficacy, surgical, and radiological outcomes of short segment occipital plate and C2 transarticular screw construct for occipito-cervical instability

Article in *Journal of Craniovertebral Junction and Spine* · October 2021

DOI: 10.4103/jcvjs.jcvjs\_113\_21

---

CITATION

1

READS

21

5 authors, including:



**Praveen Goparaju**

Yashoda Hospital

14 PUBLICATIONS 20 CITATIONS

SEE PROFILE

# Safety, efficacy, surgical, and radiological outcomes of short segment occipital plate and C2 transarticular screw construct for occipito-cervical instability

## ABSTRACT

**Objective:** Our study aims to assess the safety, efficacy, clinicoradiological, functional, neurological outcomes, and complications of posterior occipitocervical fixation using an occipital plate and C1-2 transarticular screw (TAS) construct.

**Study Design:** This was a retrospective analysis of prospectively collected data.

**Methods:** Data of 27 patients who underwent occipital plate and C1-2 TAS construct at a single institute from 2010 to 2015 were collected and analyzed. Demographics, clinical parameters (Visual Analog Score, Oswestry Disability Index, and modified JOA score), radiological parameters – mean atlantodens interval, posterior occipitocervical angle, occipitocervical-2 angle, surgical parameters (operative time, blood loss, hospital stay, and fusion), and complications were evaluated.

**Results:** The mean age of the patients was  $54.074 \pm 16.52$  years (18–81 years), the mean operative time was  $116.29 \pm 12.23$  min, and the mean blood loss was  $196.29 \pm 38.94$  ml. The mean hospital stay was  $5.22 \pm 1.28$  days. The mean  $\pm$  standard deviation follow-up duration was  $62.52 \pm 2.27$  months. There was a significant improvement in clinical parameters and radiological parameters postoperatively. One patient with implant failure, one patient with pseudoarthrosis, one with neurological deterioration, two wound complications, and two dural tears were noted.

**Conclusion:** Posterior occipitocervical reconstruction with O-C1-2 TAS construct provided excellent clinical outcomes, radiological outcomes, optimal correction of malalignment in the occipitocervical region, and with biomechanically sound fixation. Extending the instrumentation into the subaxial spine will lead to a decrease in the range of motion, increased surgical time, blood loss, more extensive muscle damage, and also increase the costs.

**Keywords:** Occipital plate C1-2 Transarticular screw construct, occipitocervical instability, short segment construct

## INTRODUCTION

Occipitocervical (OC) junction is an important and unique structure that connects the skull and the spine. It is also a highly mobile area with nearly half of the cervical flexion/extension and rotation occurs here.<sup>[1]</sup> Instability at this junction can result from various conditions including trauma, rheumatoid arthritis (RA), and other inflammatory arthropathies, congenital malformations, neoplasms, and degeneration. These patients have three-dimensional abnormalities of the junction with an anterior translation of the atlas on the axis, vertical subluxation of the odontoid process, and flexion deformity caused by anterior subluxation or dislocation of the occipitoatlantal complex on the axis.<sup>[2,3]</sup>

This can manifest a wide spectrum of symptoms ranging from mild axial neck pain to frank myelopathy.<sup>[4]</sup> OC fusion and

**PRAVEEN V. N. R. GOPARAJU, AMEYA RANGNEKAR, AMIT CHIGH, SAIJYOT SANTOSH RAUT, VISHAL KUNDNANI**

Department of Orthopaedics, Bombay Hospital and Medical Research Centre, Mumbai, Maharashtra, India

**Address for correspondence:** Dr. Praveen V. N. R. Goparaju, Bombay Hospital and Medical Research Centre, Mumbai, Maharashtra, India.  
E-mail: praveen.gvnr@gmail.com

**Submitted:** 07-Aug-21


**Accepted:** 06-Nov-21

**Published:** 11-Dec-21

This is an open access journal, and articles are distributed under the terms of the Creative Commons Attribution-NonCommercial-ShareAlike 4.0 License, which allows others to remix, tweak, and build upon the work non-commercially, as long as appropriate credit is given and the new creations are licensed under the identical terms.

**For reprints contact:** WKHLRPMedknow\_reprints@wolterskluwer.com

**How to cite this article:** Goparaju PV, Rangnekar A, Chigh A, Raut SS, Kundnani V. Safety, efficacy, surgical, and radiological outcomes of short segment occipital plate and C2 transarticular screw construct for occipito-cervical instability. *J Craniovert Jun Spine* 2021;12:381-6.

Access this article online	
<b>Website:</b> www.jcvjs.com	<b>Quick Response Code</b> 
<b>DOI:</b> 10.4103/jcvjs.jcvjs_113_21	

stabilization are the treatment of choice, for these patients. However, the high degree of mobility and the sharp angle at which the occiput meets the upper cervical spine makes rigid surgical fixation challenging.

Before the development of specific instrumentation, OC fusion was limited to *in situ* fusion, wiring, and cable techniques. Forester was the first person to perform occipitocervical reconstruction using fibular strut graft in 1927.<sup>[5]</sup> Others followed using iliac crest onlay graft after decorticating the surface.<sup>[6]</sup> However, these techniques need prolonged postoperative immobilization in the form of a Minerva jacket or halo vest. Later, wire and plate or rod constructs were developed to create more rigidity in the construct. The standard fusion technique involved fusion segment to extend until C3 or even lower because of insufficient construct stability,<sup>[7-11]</sup> and also, none of this conferred immediate rigidity and decreased the need for external immobilization. Furthermore, the sublaminar wires were associated with more incidence of dural tears and neurological injuries.<sup>[12]</sup> Now, the screw-plate-rod techniques were developed to achieve more rigid fixation and also to obviate the need for postoperative immobilization.<sup>[11]</sup> Many studies have demonstrated advantages and good outcomes with screw-plate-rod constructs over previous techniques.<sup>[13-16]</sup> Interestingly, most of the studies extended their construct to the subaxial spine to address problems at the occipitocervical junction.<sup>[12,13,16]</sup> The gamete of implants ranges from lateral mass screws to transarticular screws (TAS) in the cervical spine. To the best of our knowledge, there are many biomechanical studies to demonstrate that the instrumentation can be terminated at C2,<sup>[14,15,17,18]</sup> but few clinical studies to support the same<sup>[19,20]</sup> and no clinical studies about occipitocervical fixation with occipital plate and C1-C2 TAS (O-C1-2 TAS). Our study aims to assess the clinicoradiological efficacy with functional outcomes and complications of posterior occipitocervical fixation using an occipital plate and C2 TAS.

## METHODS

Retrospective analysis of prospectively collected data of 29 patients who underwent occipitocervical fusion (OCF) using an occipital plate and C2 TAS construct (O-C1-2 TAS) supplemented with allograft at a single institute by a senior spine surgeon from 2010 to 2015 was done by an independent observer. Two patients were lost in follow-up; therefore, 27 patients formed the study cohort. Institutional review board approval was obtained before conducting the study. Patients operated with O-C1-2 TAS fixation for any pathology with Occipitocervical instability with/without basilar invagination with minimum 5-year follow-up were

included in the study. Patients who didn't give consent and all other forms of fixation were excluded from the study.

## Surgical technique

The patient was made prone with cervical spine positioned for occipitocervical reduction while simultaneously ensuring that a trajectory for TAS placement was attainable. This required a "military tuck" position. Lateral fluoroscopic imaging was used to confirm the desired alignment before connecting the Mayfield head holder system rigidly to the table. Intraoperative traction was given to all patients. An incision was kept in the midline, from just proximal to the external occipital protuberance to the upper level of the subaxial cervical spine. Dissection was carried down through the ligamentum nuchae to the occiput proximally and the C2 spinous processes distally. Care must be taken to avoid aggressive dissection too far laterally on the posterior arch of C1.

We preferred to use an occipital plate that can accommodate both midline and lateral screws with 10–12 mm screws near the external occipital protuberance and 6–8 mm screws lateral or inferior to the external occipital protuberance placed inferior to the superior nuchal line.

For the TAS, the inferior arch of C1 and C2 was subperiosteally exposed preserving the C2–C3 interspinous ligament and facet capsule. The C2 pars interarticularis was exposed and had to be clearly defined. Before the initiation of drilling, the C1–C2 joint was opened using a McDonald or Penfield and the joint surface was curetted. The entry point and trajectory were determined based on a retrograde projection of the dorsal most and medial aspects of the C1–C2 joint line on the inferior part of the C2 lamina. A stab incision was made 1 cm lateral to the midline in the T1–T2 region and a drill guide was used. Once the drill guide was in place, a high-speed burr was used to create a starter hole in C2 at the desired entry site for drilling of the TAS. It was essential to drill as dorsally and medially as possible within the pars interarticularis to minimize potential injury to the vertebral artery (VA). In a high-riding VA, a steeper trajectory was adopted. After drilling to the anterior cortex of C1, the hole was tapped and the screw was passed. The procedure was repeated on the contralateral side.

The plate portion of the rod was slightly bent to fit the occipital contour and was fixed by self-tapping screws onto the occiput and then fixed with cervical screws after reduction and maintaining it. The reduction was achieved with traction and manipulation (distraction and extension) with a posterior soft-tissue release. If not reduced, it was fixed *in situ*. Then, posterior decompression was done in

cases that were having signs and symptoms of significant compression with correlating MR imaging. All patients received morselized allograft placed over the prepared graft bed around the rod screw construct on the exposed lamina and lateral masses at all fusion levels which were processed in the bone bank present in our institution. The case example is shown in Figure 1.

Demographic data (age and sex), clinical parameters (neck pain score – Visual Analog Score (VAS), functional score – Oswestry Disability Index (ODI), modified JOA (mJOA) score, and Mc Cormick scale) were evaluated and recorded preoperatively and postoperatively.

Radiological parameters, atlantodens interval (ADI), posterior occipitocervical angle (POCA), and occipitocervical 2 angle (OC2 angle) were evaluated preoperatively and postoperatively.

Surgical parameters – operative time, intraoperative blood loss, hospital stay and intraoperative complications (VA injury, dural tear), and postoperative complications (infection, implant loosening/pullout screw, neurological worsening) were noted.

A postoperative soft cervical collar was advised for 4 weeks, and out-of-bed mobilization was recommended as the general condition of the patient permitted postoperatively. Regular follow-up was done at 2 weeks, 3 months, 6 months, 12 months, and then yearly. Neck physiotherapy was advised at 2-week follow-up after removal of sutures.

The statistical analysis was carried out using paired Student's "t-test" and ANOVA test with  $P < 0.05$  was considered as statistically significant. Statistical analysis was done using SPSS software 20.0 (SPSS Inc., Chicago, IL, USA).

## RESULTS

The demographic data was noted [Table 1] and the mean age of the patients was  $54.074 \pm 16.52$  years (18–81 years)

with a male: female was 14:13. The mean operative time was  $116.29 \pm 12.23$  min and the mean blood loss was  $196.29 \pm 38.94$  ml. The mean hospital stay was  $5.22 \pm 1.28$  days. The mean  $\pm$  standard deviation follow-up duration was  $62.52 \pm 2.27$  months.

Eight patients had RA, five patients had tuberculosis, two patients had trauma, and 13 cases having varied complex anatomies such as Arnold–Chiari Malformation (3), Os odontoideum (2), Down's syndrome (3), Klippel–Feil syndrome (3), and neurofibromatosis (1) [Table 2].

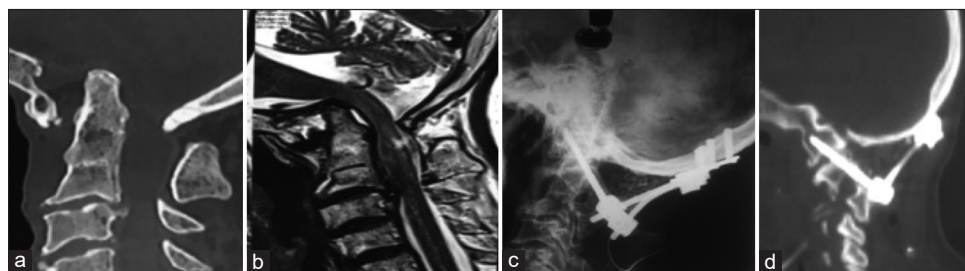
Twenty-one patients showed recovery in neurological outcomes at least in Grade 1 of Mc Cormick scale. Sixteen patients showed significant myelopathic features and all of them underwent posterior decompression procedure. Out of them, 14 patients had improvement of the mJOA scores at the last follow-up but did not improve in two patients. One patient with RA has developed subaxial subluxation and neurological deterioration.

**Table 1: Demographic data**

Parameter	Value
Age	$54.074 \pm 16.52$
Male:Female	14:13
Operative time	$116.29 \pm 12.23$
Blood loss	$196.29 \pm 38.94$
Hospital stay	$5.22 \pm 1.28$
Last follow/up	$62.52 \pm 2.27$

**Table 2: Pathologies causing occipitocervical instability**

Parameter	Value
Rheumatoid arthritis	8
Tuberculosis	5
Trauma	2
Arnold-Chiari malformations	3
Os-odontoideum	2
Downs syndrome	3
Klippel-Feil syndrome	3
Neurofibromatosis	1



**Figure 1: (a) Showing computed tomography scan of a patient with occipitocervical instability. (b) Showing magnetic resonance imaging with cord compression. (c) Indicating postoperative lateral X-ray after occipitocervical fusion. (d) Showing postoperative computed tomography scan with occipitocervical fusion**

ANOVA test was used for comparison of VAS and ODI scores [Table 3]. There was a significant difference in the value of VAS and ODI scores between preoperative values as compared to post 6 months and postoperative 5 years ( $P < 0.05$ ). *t*-test was used for comparison mJOA scores. There was a significant difference between preoperative values as compared to post 6 months and 5 years.

*t*-test was used to compare ADI, POCA, and OC2 angles preoperatively and postoperatively [Table 4]. There was a significant difference between all the parameters ( $P < 0.005$ ).

One patient developed implant failure and one patient with pseudoarthrosis was recorded. The implant failure patient has to be re-operated, while the pseudoarthrosis patient is clinically asymptomatic and was treated conservatively. One with neurological deterioration due to subaxial sublation was re-operated to extended the implants distally. Two superficial wound complications and two dural tears were noted, however, none of the cases developed life-threatening complications.

## DISCUSSION

Occipitocervical junction has a complex anatomic and biomechanical characteristic, making it uniquely challenging for the operating surgeon to treat the pathological condition at this junction. In 1927, Forester was the first person to successfully perform OC reconstruction using fibular strut graft.<sup>[5]</sup> It opened up new horizons for surgeons to treat patients effectively with OC instability. Over the years, along with evolution in surgical techniques, there is also been advancement in the implants used to improve stability and enhance fusion.<sup>[13-17]</sup> Before the development of specifically designed implants, it is limited to *in situ* fusion using autogenous bone grafts, wires, and cables.<sup>[7-11]</sup> These constructs need longer segment instrumentation to maintain stability. Even then, these techniques require external immobilization in the form of a cervical collar or halo vest for prolonged periods. The more advanced plate screw rod constructs are used now that offer immediate stability and also aid in reduction.<sup>[13-16]</sup> These instruments have been widely used with uniformly good results. Interestingly, most of the studies extended their construct to the subaxial spine.<sup>[12,13,16]</sup>

To the best of our knowledge, many biomechanical studies demonstrate that the instrumentation can be terminated at C2,<sup>[14,15,17,18]</sup> but very few clinical studies prove the same<sup>[19,20]</sup> and no clinical studies about occipitocervical fixation with occipital plate and C1-C2 TAS. Extending the instrumentation into the subaxial spine might lead to a decrease in the range of motion, increased surgical time, blood loss, more extensive muscle damage, and also increase the costs. This study aims in providing solid evidence in terms of clinicoradiological, functional, and neurological outcomes of the O-C1-2 TAS fixation technique.

In terms of surgical outcomes, fixation until C2 is expected to have certain advantages in terms of the operation time, blood loss, and total hospital stay. Because of the limited exposure and less hardware insertion, the blood loss during the surgery is expected to be less and also the operative time. The average blood loss in the study is  $196.29 \pm 38.94$  ml, which is slightly lower than the occipital-C3 construct in the study done by Pan *et al.*<sup>[19]</sup> The operative time also shows the same, with the mean operative time of  $116.29 \pm 12.23$  min in this study as compared to  $208.3 \pm 51.5$  min.<sup>[19]</sup> The mean hospital stay is  $5.22 \pm 1.28$  when compared to 6.7 days in the other study.<sup>[21]</sup> Although hospital stay cannot be the best measure for the recovery rate of the patient because it is dependent on factors other than the medical reasons such as the insurance system and also the postoperative protocols of the institute, but it gives a fairly good idea about the postoperative comfort levels of the patient.

In terms of pain scores and clinical outcomes such as VAS, ODI, and mJOAs scores, this study shows similar or having mild superiority compared to other studies.<sup>[21-24]</sup> The mean increase in mJOA score in the study is around 5 after 5 years postoperatively. It is better compared to Ogiyama *et al.*<sup>[23]</sup> study which reported an increase of 3.8 mJOAs points. The improvement in the VAS score and ODI scores is also marginally better than the other studies.<sup>[20]</sup> This explains that the reduced tissue trauma intraoperatively causes lesser neck pain and improved quality of life postoperatively.

In the study, the use of O-C1-2 TAS had a significant improvement in radiological parameters such as ADI, O-C2 angle, and POCA angle showing sufficient correction of malalignment at the craniovertebral junction. The mean ADI

**Table 3: Functional outcomes**

	Preoperative	Postoperative 6 months	Postoperative 5 years	Significance	P
VAS	6.96±1.09	2.89±0.97	2.37±1.08	Significant	<0.01 (ANOVA test)
ODI	75.29±6.06	42.8±7.73	25.48±5.05	Significant	<0.01 (ANOVA test)
mJOA	11.85±1.41	15.18±0.83	17.04±0.71	Significant	<0.01 ( <i>t</i> -test)

VAS - Visual Analog Scale score; ODI - Oswestry disability index; mJOA - Modified Japanese orthopedic association score

**Table 4: Radiological outcomes**

	Preoperative	Postoperative	P (S)
ADI	4.31±0.59	2.062±0.39	<0.01 (S)
POCA	120.52±1.31	108.19±5.47	<0.01 (S)
OC2 angle	14.78±1.34	22.22±1.086	<0.01 (S)

T-test was used. ADI - Atlantodens interval; POCA - Posterior occipitocervical angle; OC2 angle - Occipitocervical 2 angle; S - Significant

in the study is  $2.062 \pm 0.39$  mm postoperatively, which is better compared to the Eduardo Martinez-del-Campo *et al.* study showing the mean ADI of 3.2 mm.<sup>[16]</sup> The postoperative correction of O-C2 angle and POCA are similar to other studies.<sup>[20,25]</sup> The postoperative correction of radiological parameters suggests a decrease in the mechanical stress to the anterior medulla oblongata and leads to indirect decompression with relieved medullary compressive symptoms.

In a biomechanical study conducted by Martin *et al.*,<sup>[18]</sup> they compared 4°C constructs and concluded that O-C1-2 TAS is superior to O-C2 pars screw and provides stable fixation similar to the construct extending till C4 vertebra. They also concluded that the increased fusion segment extending to C4 in OCF does not significantly reduce the cervical junction range of motion. However, this result was demonstrated only *in vitro*, and further *in vivo* research is needed to determine whether the conclusion will be the same in the clinical scenario. All the movements such as flexion, extension, lateral bending, and rotations show slightly higher values in our study compared to this biomechanical study. Another biomechanical study conducted by Finn *et al.*<sup>[17]</sup> compared the relative immediate stiffness for occipital plate fixation in concordance with TAS fixation (O-C1-2 TAS), C-1 lateral mass and C-2 pars screw (C1 L-C2P), and C-1 lateral mass and C-2 laminar screw (C1 L-C2 L) constructs and concluded that the C1 L-C2P and O-C1-2 TAS performed better than C1 L-C2 L construct.

We had a long-term follow-up of 5 years and had only one case of implant failure at 10 months postoperatively as compared to 8 in the study by Ando *et al.*<sup>[26]</sup> Pseudo-arthritis is seen in 2 out of 27 patients which is comparable to other studies. Kukreja<sup>[27]</sup> reported 4 out of 49 patients with nonunion at the final follow-up and Nockels *et al.*<sup>[28]</sup> showed 2 out of 69 patients with nonunion. One patient with RA has developed subaxial subluxation and neurological deterioration. Two patients developed wound complications and two patients developed dural tears. However, none of the cases developed life-threatening complications. The overall complication rates of our study are comparable to those done by Lee *et al.*<sup>[29]</sup> (6.25%) and those of Choi *et al.*<sup>[30]</sup> (18.75%).

The primary strength of our study is that it represents a large series of occipital-C1-2 transarticular screws with a long-term follow-up of 5 years to date. The retrospective study design, however, does limit the strength of the conclusions that can be drawn. Furthermore, as a single-surgeon, single-institution study, the reported results may not be generalizable.

## CONCLUSION

Posterior occipitocervical reconstruction with O-C1-2 TAS constructs provided excellent clinical outcomes, radiological outcomes, optimal correction of malalignment in the occipitocervical region, and with biomechanically sound fixation. Extending the instrumentation into the subaxial spine will lead to a decrease in the range of motion, increased surgical time, blood loss, more extensive muscle damage, and also increase the costs. This makes this technique a valuable procedure for the management of atlantoaxial instability.

## Financial support and sponsorship

Nil.

## Conflicts of interest

There are no conflicts of interest.

## REFERENCES

- Lu DC, Roeser AC, Mummaneni VP, Mummaneni PV. Nuances of occipitocervical fixation. *Neurosurgery* 2010;66:141-6.
- Sandhu FA, Pait TG, Benzel E, Henderson FC. Occipitocervical fusion for rheumatoid arthritis using the inside-outside stabilization technique. *Spine (Phila Pa 1976)* 2003;28:414-9.
- Ebraheim N, Rollins JR Jr., Xu R, Jackson WT. Anatomic consideration of C2 pedicle screw placement. *Spine (Phila Pa 1976)* 1996;21:691-5.
- Smith MD, Anderson P, Grady MS. Occipitocervical arthrodesis using contoured plate fixation. An early report on a versatile fixation technique. *Spine (Phila Pa 1976)* 1993;18:1984-90.
- S. A. K. W. Die Leitungsbahnen des Schmerzgeföhls und die chirurgische Behandlung der Schmerzzustände. *J Neurol Psychopathol* 1927;8:85-6.
- Newman P, Sweetnam R. Occipito-cervical fusion. An operative technique and its indications. *J Bone Joint Surg Br* 1969;51:423-31.
- Cone W, Turner WG. The treatment of fracture-dislocations of the cervical vertebrae by skeletal traction and fusion. *J Bone Joint Surg* 1937;19:584-602.
- Hamblen DL. Occipito-cervical fusion. Indications, technique and results. *J Bone Joint Surg Br* 1967;49:33-45.
- Jain VK, Takayasu M, Singh S, Chharbra DK, Sugita K. Occipital-axis posterior wiring and fusion for atlantoaxial dislocation associated with occipitalization of the atlas. Technical note. *J Neurosurg* 1993;79:142-4.
- MacKenzie AI, Uttley D, Marsh HT, Bell BA. Craniocervical stabilization using Luque/Hartshill rectangles. *Neurosurgery* 1990;26:32-6.
- Malcolm GP, Ransford AO, Crookard HA. Treatment of non-rheumatoid occipitocervical instability. Internal fixation with the Hartshill-Ransford loop. *J Bone Joint Surg Br* 1994;76:357-66.
- Vaccaro AR, Lim MR, Lee JY. Indications for surgery and stabilization techniques of the occipito-cervical junction. *Injury* 2005;36 Suppl 2:B44-53.

13. Puttlitz CM, Melcher RP, Kleinstueck FS, Harms J, Bradford DS, Lotz JC. Stability analysis of craniovertebral junction fixation techniques. *J Bone Joint Surg Am* 2004;86:561-8.
14. Sutterlin CE 3<sup>rd</sup>, Bianchi JR, Kunz DN, Zdeblick TA, Johnson WM, Rapoff AJ. Biomechanical evaluation of occipitocervical fixation devices. *J Spinal Disord* 2001;14:185-92.
15. Oda I, Abumi K, Sell LC, Haggerty CJ, Cunningham BW, McAfee PC. Biomechanical evaluation of five different occipito-atlanto-axial fixation techniques. *Spine (Phila Pa 1976)* 1999;24:2377-82.
16. Martinez-Del-Campo E, Turner JD, Kalb S, Rangel-Castilla L, Perez-Orribe L, Soriano-Baron H, *et al.* Occipitocervical fixation: A single surgeon's experience with 120 patients. *Neurosurgery* 2016;79:549-60.
17. Finn MA, Fassett DR, Mccall TD, Clark R, Dailey AT, Brodke DS. The cervical end of an occipitocervical fusion: A biomechanical evaluation of 3 constructs. Laboratory investigation. *J Neurosurg Spine* 2008;9:296-300.
18. Martin MD, Bruner HJ, Wolfla CE, Yoganandan N. Biomechanical implications of extending occipitocervical instrumentation to include the subaxial spine. *Neurosurgery* 2010;66:1148-52.
19. Pan J, Huang D, Hao D, Zhao Y, He B, Wu Q, *et al.* Occipitocervical fusion: Fix to C2 or C3? *Clin Neurol Neurosurg* 2014;127:134-9.
20. Tian W, Weng C, Li Q, Liu B, Sun YQ, Yuan Q, *et al.* Occipital-C2 transarticular fixation for occipitocervical instability associated with occipitalization of the atlas in patients with klippel-feil syndrome, using intraoperative 3-dimensional navigation system. *Spine (Phila Pa 1976)* 2013;38:642-9.
21. Upadhyaya M, Jain S, Kire N, Merchant Z, Kundnani V, Patel A. Surgical, clinical, and radiological outcomes of occipitocervical fusion using the plate-screw-rod system with allograft in craniocervical instability. *J Craniovertebr Junction Spine* 2019;10:216-23.
22. Winegar CD, Lawrence JP, Friel BC, Fernandez C, Hong J, Maltenfort M, *et al.* A systematic review of occipital cervical fusion: Techniques and outcomes. *J Neurosurg Spine* 2010;13:5-16.
23. Ogihara N, Takahashi J, Hirabayashi H, Hashidate H, Kato H. Long-term results of computer-assisted posterior occipitocervical reconstruction. *World Neurosurg* 2010;73:722-8.
24. Hwang SW, Gressot LV, Rangel-Castilla L, Whitehead WE, Curry DJ, Bollo RJ, *et al.* Outcomes of instrumented fusion in the pediatric cervical spine. *J Neurosurg Spine* 2012;17:397-409.
25. Guan J, Jian F, Yao Q, Yuan C, Zhang C, Ma L, *et al.* Quantitative reduction of basilar invagination with atlantoaxial dislocation by a posterior approach. *Neurospine* 2020;17:574-84.
26. Ando K, Imagama S, Ito Z, Kobayashi K, Yagi H, Shinjo R, *et al.* Minimum 5-year follow-up results for occipitocervical fusion using the screw-rod system in craniocervical instability. *Clin Spine Surg* 2017;30:E628-32.
27. Kukreja S, Ambekar S, Sin AH, Nanda A. Occipitocervical fusion surgery: Review of operative techniques and results. *J Neurol Surg B Skull Base* 2015;76:331-9.
28. Nockels RP, Shaffrey CI, Kanter AS, Azeem S, York JE. Occipitocervical fusion with rigid internal fixation: Long-term follow-up data in 69 patients. *J Neurosurg Spine* 2007;7:117-23.
29. Lee SC, Chen JF, Lee ST. Clinical experience with rigid occipitocervical fusion in the management of traumatic upper cervical spinal instability. *J Clin Neurosci* 2006;13:193-8.
30. Choi SH, Lee SG, Park CW, Kim WK, Yoo CJ, Son S. Surgical outcomes and complications after occipito-cervical fusion using the screw-rod system in craniocervical instability. *J Korean Neurosurg Soc* 2013;53:223-7.